



This article appeared in a journal published by Elsevier. The attached copy is furnished to the author for internal non-commercial research and education use, including for instruction at the author's institution and sharing with colleagues.

Other uses, including reproduction and distribution, or selling or licensing copies, or posting to personal, institutional or third party websites are prohibited.

In most cases authors are permitted to post their version of the article (e.g. in Word or Tex form) to their personal website or institutional repository. Authors requiring further information regarding Elsevier's archiving and manuscript policies are encouraged to visit:

<http://www.elsevier.com/authorsrights>

**Re: Prostate-specific Membrane Antigen PET-CT in Patients with High-risk Prostate Cancer Before Curative-intent Surgery or Radiotherapy (proPSMA): A Prospective, Randomised, Multi-centre Study**

Hofman MS, Lawrentschuk N, Francis RJ, et al  
Lancet 2020;395:1209–16

**Expert's summary:**

In this randomised study, the authors compared the performance of prostate-specific membrane antigen (PSMA) positron emission tomography (PET)-computed tomography (CT) versus conventional imaging in 302 men with high-risk prostate cancer (prostate-specific antigen >20 ng/ml, grade group 3–5, clinical stage  $\geq$  T3) [1]. The primary endpoint was the performance (patient-level analysis) of imaging for detecting either nodal or distant metastatic disease. PSMA PET-CT had a 27% absolute greater area under the receiver operating characteristic curve for accuracy than conventional imaging, and higher sensitivity (85% vs 38%) and specificity (98% vs 91%). The number of equivocal lesions was reduced by approximately three when PSMA PET-CT was used compared with conventional imaging. A clinical management change was considered in 15% of men undergoing conventional imaging after randomisation, compared with 28% in men undergoing PSMA PET-CT ( $p = 0.008$ ).

**Expert's comments:**

Novel imaging tools such as PET-CT have been developed to more accurately detect disease with low metastatic burden and potentially modify cancer management and improve outcomes [2,3]. These assumptions are attributed to a higher tumour-to-background contrast and to the radiotracer specificity for prostate cancer cells. However, until this publication, firm prospective comparative data were missing in the context of preoperative assessment. This randomised trial confirms with a high level of evidence that PSMA PET-CT outperforms conventional imaging for detection of metastatic disease in the setting of presumably localised high-risk prostate cancer in men who are candidates for radical treatment of the primary tumour. It demonstrates that PSMA PET-CT can (or should) replace conventional imaging given its meaningful impact on treatment decision-making. The main limitation is that histological confirmation of metastatic tissue was not

systematically achieved for all participants, even though biopsy of suspected sites was strongly encouraged in the protocol. Nevertheless, the authors included 6-mo repeat imaging to confirm or not the metastatic nature of equivocal lesions. On the basis of these findings, PSMA PET-CT undoubtedly improves the snapshot of high-risk disease. However, we do not really know to date if this improvement in detection leads to better disease management or better outcomes. One can argue that this high-resolution imaging, if positive, could lead to undertreatment of the primary tumour. Nevertheless, given the available literature on oligometastatic disease, the advent of PET-CT as a staging tool could improve the management of these patients at high risk of recurrence via early targeting of small metastatic lesions using stereotactic body radiotherapy and/or a more aggressive multimodal strategy [4,5].

**Conflicts of interest:** The author has nothing to disclose.

**References**

- [1] Hofman MS, Lawrentschuk N, Francis RJ, et al. Prostate-specific membrane antigen PET-CT in patients with high-risk prostate cancer before curative-intent surgery or radiotherapy (proPSMA): a prospective, randomised, multicentre study. *Lancet* 2020;395:1208–16.
- [2] Perera M, Papa N, Roberts M, et al. Gallium-68 prostate-specific membrane antigen positron emission tomography in advanced prostate cancer-updated diagnostic utility, sensitivity, specificity, and distribution of prostate-specific membrane antigen-avid lesions: a systematic review and meta-analysis. *Eur Urol* 2020;77:403–17.
- [3] Fendler WP, Calais J, Eiber M, et al. Assessment of 68Ga-PSMA-11 PET accuracy in localizing recurrent prostate cancer: a prospective single-arm clinical trial. *JAMA Oncol* 2019;5:856–63.
- [4] Parker CC, James ND, Brawley CD, et al. Radiotherapy to the primary tumour for newly diagnosed, metastatic prostate cancer (STAMPEDE): a randomised controlled phase 3 trial. *Lancet* 2018;392:2353–66.
- [5] Ost P, Reynnders D, Decaestecker K, et al. Surveillance or metastasis-directed therapy for oligometastatic prostate cancer recurrence: a prospective, randomized, multicenter phase II trial. *J Clin Oncol* 2018;36:446–53.

Guillaume Ploussard<sup>a,\*</sup>

<sup>a</sup>Department of Urology, La Croix du Sud Hospital, Quint Fonsegrives, France

\*Corresponding author: Department of Urology, La Croix du Sud Hospital, 52, chemin de Ribaute, Quint Fonsegrives, 31130, France  
E-mail address: g.ploussard@gmail.com.

**Re: Variability of the Positive Predictive Value of PI-RADS for Prostate MRI Across 26 Centers: Experience of the Society of Abdominal Radiology Prostate Cancer Disease-focused Panel**

Westphalen AC, McCulloch CE, Anaokar JM, et al  
Radiology 2020;296:76–84

**Experts' summary:**

The Society of Abdominal Radiology Prostate Cancer Disease panel recently reported a retrospective, cross-sectional study

evaluating the ability of prostate magnetic resonance imaging (MRI) to detect International Society of Urological Pathology (ISUP) grade group  $\geq 2$  (GG  $\geq 2$ ) cancer at multiple centres [1]. The study goal was to document variability in GG  $\geq 2$  cancer detection and provide a snapshot of MRI performance in mostly academic US centres. Data for a heterogeneous cohort of 3449 men with Prostate Imaging-Reporting and Data System (PI-RADS) from two to five lesions (biopsy-naïve 38%, prior biopsy with positive and negative histology 56%, unknown 6%) were analysed as a single pool. Concomitant systematic transrectal ultrasound-guided biopsy (SB) was

performed in 92%. The incidence of  $GG \geq 2$  cancers was 49% (Fig. 1).

The positive predictive value (PPV) variance by PI-RADS category was chosen as the measure for test performance. We believe that the report mistakenly ascribed the PPV variability observed to the PI-RADS assessment without considering multiple sources of heterogeneity.

#### Experts' comments:

MRI scans were evaluated by practice-based radiologists using PI-RADS assessment as part of standard clinical care [2]. The final report and not the MRI scans were reviewed. The authors failed to account for variables such as MR field strength, scanner vendor, endorectal coil use, image quality, reader quality, MRI positivity threshold for biopsy, biopsy-targeting method, experience of biopsy operators, need for SB samples, pathological expertise, or adherence to the ISUP consensus on Gleason grading [3]. The experience and biopsy performance of the 140 interpreting radiologists ( $n=89$ ) must inevitably vary across centres. The experience of the physicians performing biopsies and the radiological interactions for prostate and target delineations and ultrasound-MRI data fusion were not reported. Concomitant systematic biopsies were performed in most patients and analysed separately. Unfortunately, the expertise of the pathologists is also not described.

Three analyses were conducted: (1) model-based estimates of PPV at lesion level; (2) lesion-based intercentre PPV variability, evaluated as the median and interquartile range by PI-RADS category; and (3) patient-level benefits of the MRI pathway, compared in a subset undergoing both SB and targeted biopsies. The authors comment on two principal observations. First, men undergoing MRI-targeted biopsy demonstrate an overall low lesion-level PPV. Second,

there is wide intercentre PPV variance regardless of the PI-RADS category cutoff used.

#### Lesion-level MRI pathway performance

PI-RADS assessment behaved properly, showing increasing rates of  $GG \geq 2$  cancers with increasing PI-RADS suspicion categories. The estimated PPV for PI-RADS assessment categories was 5% for PI-RADS 2, 15% for PI-RADS 3, 39% for PI-RADS 4, and 72% for PI-RADS 5. These data are in line with a recent meta-analysis by Barkovich et al [4].

Westphalen et al [1] emphasized the “low” lesion-level PPV (35%). There are two explanations for this seemingly “low” PPV. First, the case mix: the overall lesion PPV will be higher if more PI-RADS 4–5 findings are included and correspondingly will decrease with inclusion of more PI-RADS 2–3 lesions [5]. They included a high number of PI-RADS 2–3 lesions (40%), which automatically lowers the lesion-level PPV because of the lower prevalence of  $GG \geq 2$  cancers [1,4].

Second, PPV depends on disease prevalence in the study cohort. Some centres included men with prior positive biopsies with  $GG \geq 2$  cancers. It seems likely that urologists selected men for MRI-guided biopsy when they were uncertain about tumour grade. These lesions are likely to be smaller  $GG \geq 2$  cancers, which would reduce the PI-RADS 5 category and thus lower the PPV. These factors should have been mentioned as limitations if lesion-level PPV is adopted as a benchmark.

#### Intercentre lesion PPV variability

The authors noted wide intercentre lesion PPV variability. Multiple factors can affect the ability of the MRI pathway to detect  $GG \geq 2$ . As mentioned, the leading issue is disease

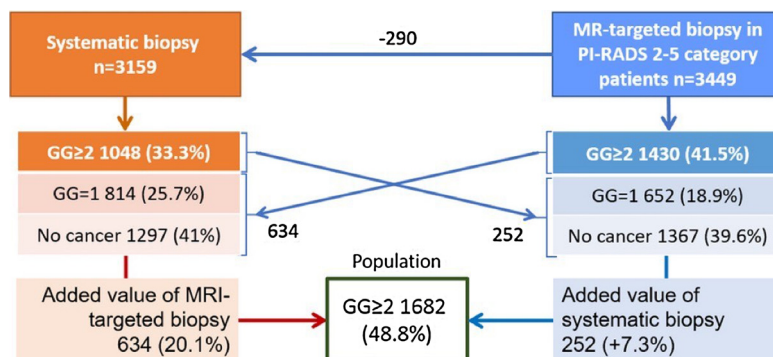


Fig. 1 – Patient flows and biopsy results for the study by Westphalen et al [1]. Only men undergoing targeted biopsies were analysed; 90% underwent systematic biopsies (selection criteria unknown), that is, 290 patients had only targeted biopsies.

GG=International Society of Urological Pathology grade group; MRI=magnetic resonance imaging; PI-RADS=Prostate Imaging-Reporting and Data System.

prevalence in the patient cohort. Statistical corrections in the study did not address the heterogeneous case mix at the centres (Fig. 2). As a result, the PPV for each centre differed. Furthermore, essential factors affecting the entire MRI pathway and thus the lesion PPV were not systematically considered [6–8]. There were no assessments of image quality, resulting in variable quality. The training and experience of the interpreting radiologists varied and are undocumented. Finally, there is likely to be wide inter-rater variability for GG scoring [9].

#### MRI pathway performance

The authors expressed concerns regarding the reliability of PI-RADS because of the high intercentre PPV variability. However, it is important to emphasise that the most important benefit of prostate MRI for biopsy-naïve men is its high patient-level negative predictive value (NPV) for GG > 2 cancers, rather than its lesion-based PPV. A high patient-level NPV allows biopsy avoidance in a substantial percentage of men and reduces the rate of detection of GG 1 cancer [10]. In this study we cannot estimate the patient-level variability of NPV because negative cases were not submitted for the review process.

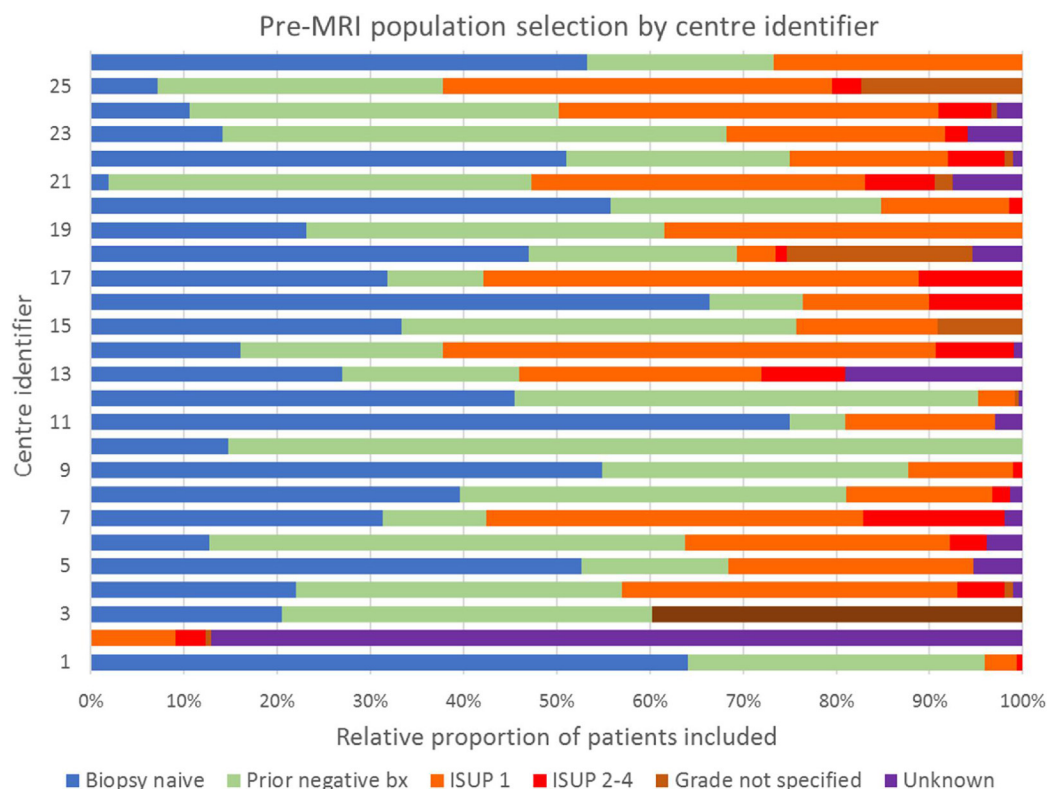
**Table 1 – Steps to achieving end-to-end quality in the MRI prostate cancer diagnostic pathway.<sup>a</sup>**

Element	Comments
Patients	Risk-based selection
MRI data acquisition	Quality assurance and quality control of MRI machines, PI-RADS standard compliance, technologist expertise
MRI reading	Experienced readers
Selection for biopsy	Multidisciplinary team
Prebiopsy preparations	Prostate gland and target delineations and MRI-US data fusion
MRI-targeted biopsies	Skilled operators
Histopathology	Experienced pathologists

MRI = magnetic resonance imaging; PI-RADS = Prostate Imaging-Reporting and Data System; US = ultrasound.

<sup>a</sup> Multiple elements must be coordinated for successful use of MRI for prostate cancer diagnosis. Diagnostic units require quality assurance programs, quality control of MRI and pathology evaluations, and trained individuals working within multidisciplinary teams.

Unlike the PPV, the NPV is less susceptible to operator biopsy performance and histopathological errors. Interestingly, the value of adding MRI biopsy to SB was high (20.1%; Fig. 1) compared to the Cochrane meta-analysis (10.9%) [11].



**Fig. 2 – Heterogeneity in patient case mix at each centre. The case mix at participating centres was very heterogeneous, resulting in differing prevalence according to the proportion of each patient group included.**

ISUP = International Society of Urological Pathology.

## Conclusions

The title and take-home messages from the paper by Westphalen et al [1] may give a false impression that PI-RADS assessments appear to be underperforming. It is incorrect to suggest that the wide intercentre PPV indicates poor PI-RADS performance. Careful analysis of the data shows that the PI-RADS assessment performs well, as designed. The known patient benefits of MRI for detecting GG  $\geq 2$  cancers over SB are observable, even in this heterogeneous cohort. It must be emphasized again that the clinical benefits of the MRI pathway arise from its high patient-level NPV and not the PPV, which allows biopsy avoidance and reduces the detection rate of GG 1 cancer.

The PPV shows considerable intercentre variability caused by heterogeneities across the entire MRI pathway, from patient selection to MR image quality, to reading quality, to biopsy performance and pathological experience. It is essential to ensure that all individuals involved in the MRI pathway workflow are competent, and that quality controls and quality assurance procedures are in place at prostate MRI facilities (Table 1). The most important lesson from this paper is the high intercentre PPV variability, which clearly indicates the constant need to improve end-to-end quality in the MRI-directed diagnostic process.

**Conflicts of interest:** The authors have nothing to disclose.

## References

- [1] Westphalen AC, et al. Variability of the positive predictive value of PI-RADS for prostate MRI across 26 centers: experience of the Society of Abdominal Radiology Prostate Cancer Disease-focused Panel. *Radiology* 2020;296:76–84.
- [2] Weinreb JC, et al. PI-RADS Prostate Imaging-Reporting and Data System: 2015, version 2. *Eur Urol* 2016;69:16–40.
- [3] Epstein JI, et al. The 2014 International Society of Urological Pathology (ISUP) Consensus Conference on Gleason Grading of Prostatic Carcinoma: definition of grading patterns and proposal for a new grading system. *Am J Surg Pathol* 2016;40:244–52.
- [4] Barkovich EJ, et al. A systematic review of the existing Prostate Imaging Reporting and Data System version 2 (PI-RADSv2) literature and subset meta-analysis of PI-RADSv2 categories stratified by Gleason scores. *Am J Roentgenol* 2019;212:847–54.
- [5] Moldovan PC, et al. What is the negative predictive value of multiparametric magnetic resonance imaging in excluding prostate cancer at biopsy? A systematic review and meta-analysis from the European Association of Urology Prostate Cancer Guidelines Panel. *Eur Urol* 2017;72:250–66.
- [6] Kasabwala K, et al. The learning curve for magnetic resonance imaging/ultrasound fusion-guided prostate biopsy. *Eur Urol Oncol* 2019;2:135–40.
- [7] Gordetsky JB, et al. MRI-targeted prostate biopsy: key considerations for pathologists. *Histopathology*. In press. <https://doi.org/10.1111/his.14113>.
- [8] Gaziev G, et al. Defining the learning curve for multiparametric magnetic resonance imaging (MRI) of the prostate using MRI-transrectal ultrasonography (TRUS) fusion-guided transperineal prostate biopsies as a validation tool. *BJU Int* 2016;117:80–6.
- [9] Shah MD, et al. Impact of the pathologist on prostate biopsy diagnosis and immunohistochemical stain usage within a single institution. *Am J Clin Pathol* 2017;148:494–501.
- [10] Padhani AR, et al. Prostate Imaging-Reporting and Data System Steering Committee: PI-RADS v2 status update and future directions. *Eur Urol* 2018;75:385–96.
- [11] Drost F-JH, et al. Prostate magnetic resonance imaging, with or without magnetic resonance imaging-targeted biopsy, and systematic biopsy for detecting prostate cancer: a Cochrane systematic review and meta-analysis. *Eur Urol* 2020;77:78–94.
- [12] Ahdoot M, et al. MRI-targeted, systematic, and combined biopsy for prostate cancer diagnosis. *N Engl J Med* 2020;382:917–28.

Anwar R. Padhani<sup>a</sup>, Jelle Barentsz<sup>b,\*</sup>, Jeffrey Weinreb<sup>c</sup>, Ivo Schoots<sup>d</sup>, Clare Tempany<sup>e</sup>

<sup>a</sup>Paul Strickland Scanner Centre, Mount Vernon Cancer Centre, Northwood, UK

<sup>b</sup>Department of Radiology, Nuclear Medicine, and Anatomy, Radboud University Medical Center, Nijmegen, The Netherlands

<sup>c</sup>Department of Radiology and Biomedical Imaging, Yale School of Medicine, New Haven, CT, USA

<sup>d</sup>Department of Radiology and Nuclear Medicine, Erasmus MC University Medical Center, Rotterdam, The Netherlands

<sup>e</sup>Department of Radiology, Brigham and Women's Hospital, Boston, MA, USA

\*Corresponding author. Department of Radiology, Nuclear Medicine, and Anatomy, Radboud University Medical Center, Geert Grooteplein 10, P.O. Box 9101, 6500 HB Nijmegen, The Netherlands.

E-mail address: [jelle.barentsz@radboudumc.nl](mailto:jelle.barentsz@radboudumc.nl) (J. Barentsz).

<https://doi.org/10.1016/j.euo.2018.07.005>